BALT INTERNATIONAL

CASE REPORT

Endovascular approach to Aortic Coarctation. A case report.

Authors: Dr. Gerard Mertikian[1]
Email: gmertikian@hotmail.com
[1] Institute of Radiology, Hietzing Hospital, Department of Interventional Radiology Vienna-Austria

Abstract: Aortic coarctation is a very rare condition in the adult, with an incidence of 3-4/ 1000 live births. The tight narrowing of the aorta is usually located in the descending thoracic aorta, but can at times be seen in the abdominal aorta. The narrowing causes arterial hypertension in the upper limbs, congestive heart failure and claudication of the lower limbs. Depending on the extent of the narrowing a vast network of thoracic collaterals will be encountered. The best treatment of choice is discussed controversially and can either entail an open surgical repair or an endovascular approach.

Case report

A 31 year old Armenian refugee presented himself to our hospital with lower limb claudication, exertion dyspnea and uncontrollable upper limb arterial hypertension. The CT-scan demonstrated a high grade narrowing of the thoracic aorta below the left subclavian artery, a massive collateral network and hypertrophied internal thoracic arteries. The lumen of the aorta at the left subclavian measured about 24mm; a mere 5mm at the tightest stenosis; and 22 mm downstream the stenosis. (FIG. 1,2)
In agreement with the team of cardio-vascular surgery it was decided to take an endovascular approach in treating the patient by placing an uncovered stent at the level of the lumen narrowing of the descending aorta.
Our Institution has over the years treated altogether four patients with aortic coarctation by interventional means. The technical success and the encouraging short- and long-term follow-up results in this small group of patients swung our decision towards an endovascular approach.
To be able to act quickly, we routinely perform a surgical cut-down of the contralateral groin to facilitate the introduction of a thoracic endograft of an appropriate size, in case of aortic disruption of the descending aorta post stent deployment.

FIG 1. Pre-interventional CT angiography

Fig 2. Diagnostic catheter angiography

Under general anaesthesia a surgical cut down was performed of the left groin. The right groin was punctured percutaneously, a 10 F sheath (St. Jude) placed and a guide wire passed in the descending aorta. The tight aortic stenosis was negotiated with a stiff angled Terumo guide wire (0,035 in), over which a pigtail catheter was then passed into the ascending aorta. The stenosis was crossed likewise from the left groin after having placed a 5F St. Jude sheath. A diagnostic angiography was performed delineating the stenosis and demarcating the massive collaterals. Prior to the implantation of a 30/50mm calibrated Sinus-XL self-expandable stent (Optimed) it was decided to perform a pre-dilatation utilizing a Cristal balloon (30/60mm) to probe the elasticity of the vessel wall and to create a sufficiently large enough lumen for the stent. A control angiography showed a marked improvement of the aortic lumen. The Sinus-XL stent was then deployed with its proximal edge abutting the left subcalvian artery. A PTA was then performed using a non-compliant 10F Maxi LD 18/40mm balloon (Cordis). The control angiography showed a satisfactory result with diminished appearance of the collaterals.
The 9 F Cristal balloon (Balt) has a shaft length of 110 cm and is a semi-compliant balloon. The balloon length is 6cm and a diameter of 30 mm can be achieved by inflating the balloon to 3 bar. The Cristal balloon is a dedicated valvuloplasty device with a limited use in interventional radiology. We have in the past used the balloon in treating Type Ia endoleaks after EVAR, by mounting a Palmaz stent over the balloon. In aortic coarctation a semi-compliant can be useful in probing the elasticity and compliance of the vessel wall prior to stent placement and dilatation with a non-compliant balloon.

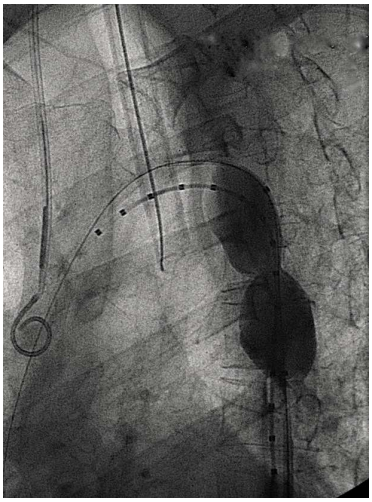

Fig 3. Cristal balloon 30/60mm

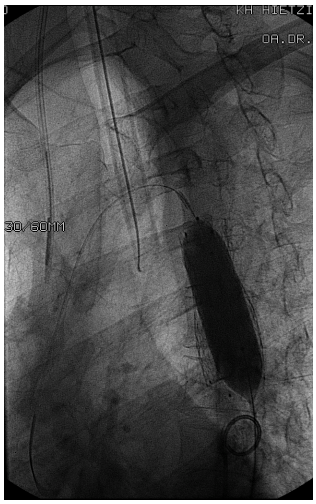

Fig 4. Sinus-XL stent/PTA 18/40mm

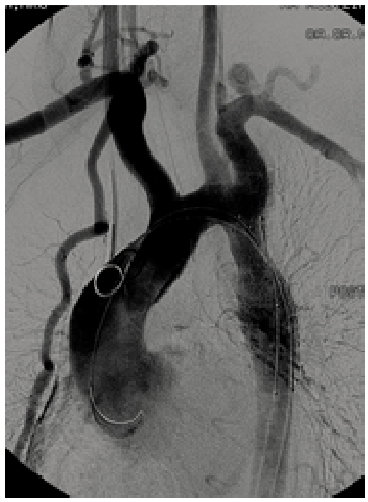

Fig 5. Completion angio

Follow-up technique and outcomes

The patient had an uneventful recovery post-operatively. He demonstrated strong palpable pulses of the common femoral arteries with an almost complete normalisation of the arterial hypertension. Postoperative CT-scan showed a good position of the stent in the descending aorta with diminished opacification of the collaterals. The patient was discharged on day 5 post op.

Discussion

The coarctation of the aorta is a congenital narrowing of the aorta usually located in the descending aorta, rarely afflicting the abdominal aorta. Depending on how tight the stenosis is, a marked difference in blood pressure between the upper and lower extremities can be encountered often causing an unctrollable hypertension in the upper limbs, a congestive heart failure with dyspnoea at exertion and lower limb claudication of varying degree.Up to the mid 1980´s open surgery was the treatment of choice. With the evolution of endovascular methods, plain angioplasty at first, balloon mounted and self-expandable stents and thoracic endografts of late have been employed as alternatives.

The literature available on endovascular techniques reports a favourable post-procedural outcome both in short and mid-term follow-ups, with a high technical success rate and a low complication rate, albeit in a mixed population of children and adults. By the same token depending on the operator's preference the endovascular approach can vary significantly. Some advocate balloon angioplasty alone in children, others prefer balloon mounted stents or self-expandable stents and yet others will opt for covered endografts.

Possible complications entail aortic disruption, dissection, intima tear with subsequent intramural haematoma, aneurysm formation, re-coarctation and stent displacement.

All studies related to this subject are invariably retrospective investigations. Solid evidence for either open surgical repair or endovascular treatment is therefore hard to come by. In our limited experience of having treated 4 adults with aortic coarctation, the endovascular option seems to be a safe and effective alternative to open surgery. Controlled randomized trials with long-term follow-ups comparing open surgery to endovascular treatment options will be mandatory to provide the evidence necessary for a standardized approach.

References

Percutaneous interventions on severe coarctation of the aorta: a 21-year experience Pediatr Cardiol. 2005 Mar-Apr;26(2):176-89

Comparing balloon angioplasty, stenting and surgery in the treatment of aortic coarctation Expert Rev Cardiovasc Ther. 2009 Nov;7(11):1401-12. Doi: 10.1586/erc.09.111

Stent implantation for aortic coarctation and recoarctation Heart 1999;82:600-606 doi:10.1136/hrt.82.5.600

Long-term follow-up results of balloon angioplasty of postoperative aortic recoarctation Am J Cardiol. 1998 Jan 1;81(1):61-7

Balloon expandable stent implantation for native and recurrent coarctation oft he aorta-prospective computed tomography assessment of stent integrity, aneurysm formation and stenosis relief Heart 2010

Immediate and follow-up findings after stent treatment for severe coarctation of aorta Am J Cardiolo. 1999 Feb 1;83(3):400-6

Procedural results and acute complications in stenting native and recurrent coarctation oft he aorta in patients over 4 years of age: a multi-institutional study Catheter Cardiovasc Interv. 2007 Aug 1;70(2):276-85